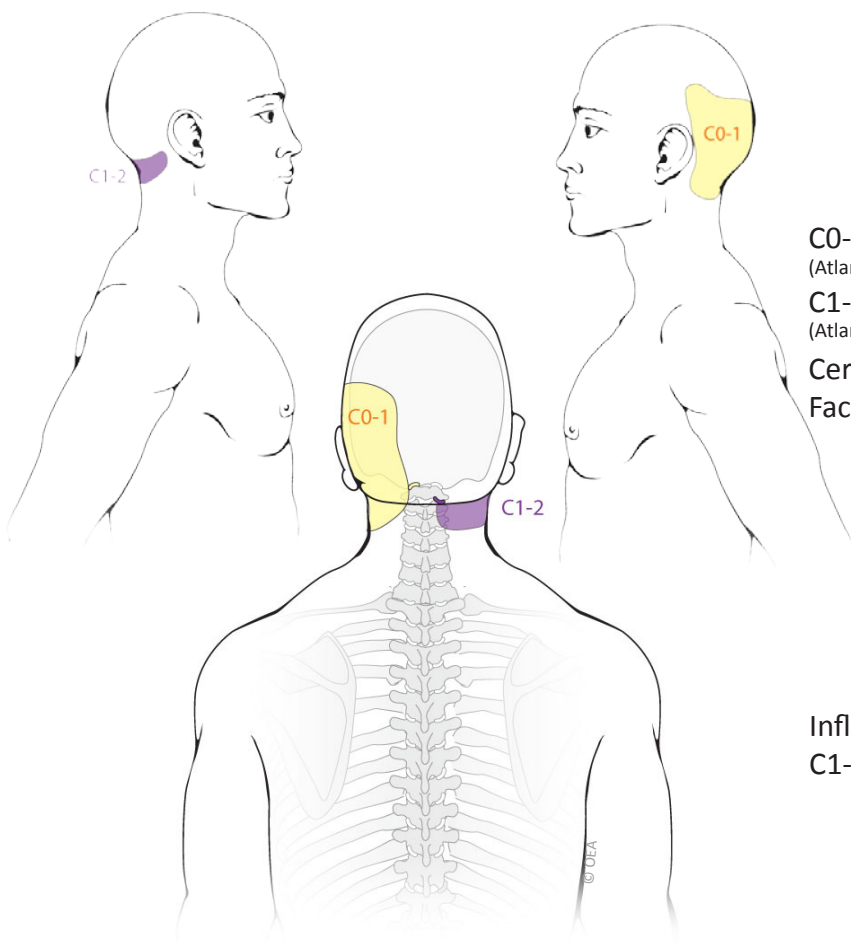
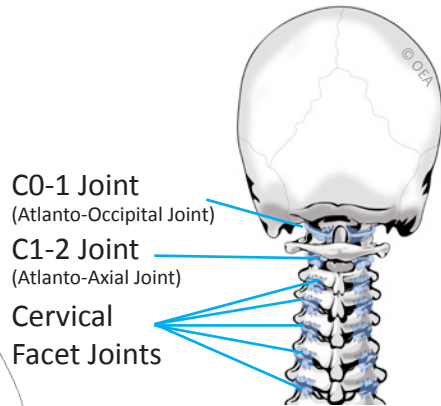


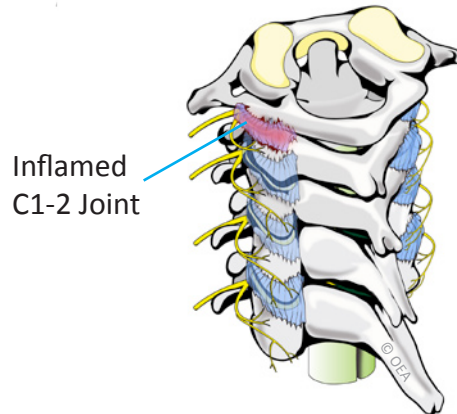
C0-1 and C1-2 Joint Pain Patterns



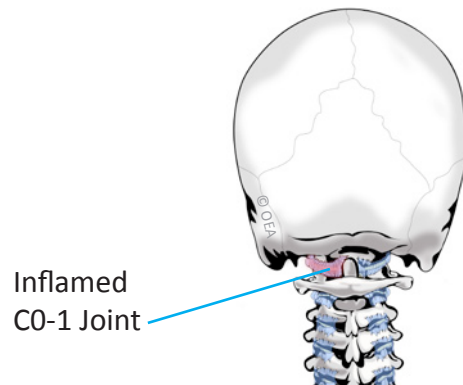
Normal Anatomy



C1-2 Synovitis



C0-1 Synovitis



Based on: Dreyfuss P, Michaelsen M, Fletcher D. Atlanto-occipital and lateral atlanto-axial joint pain patterns. *Spine*. 1994; 19(10):1125-31.



Tara M. Sheridan, M.D.
Pain Medicine/Anesthesiology



31469 Rancho Pueblo Road,
Suite 101
Temecula, CA 92592
Phone: 951-303-3718
Fax: 951-303-0451