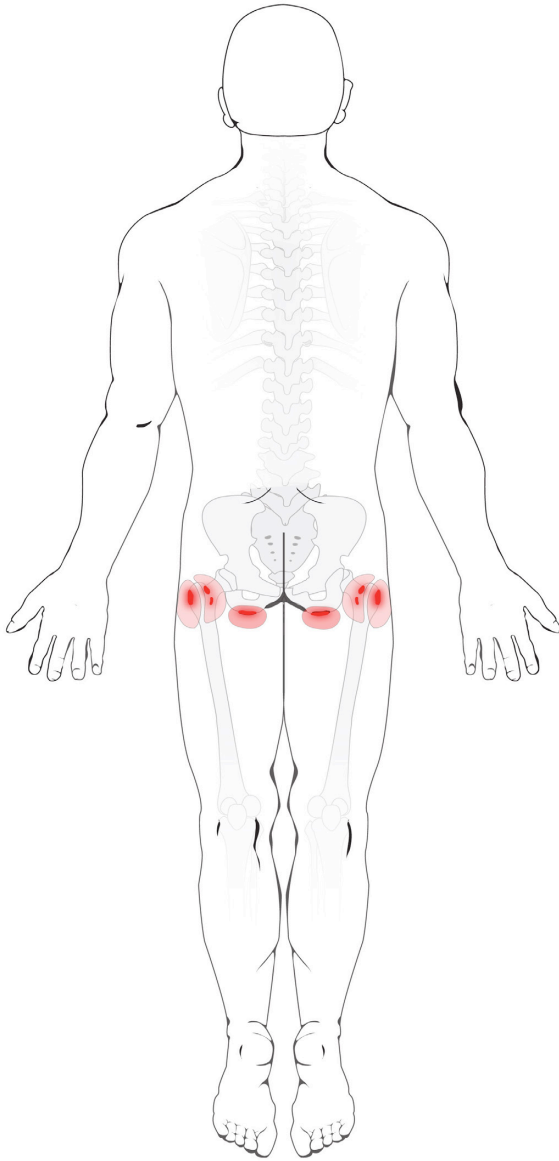


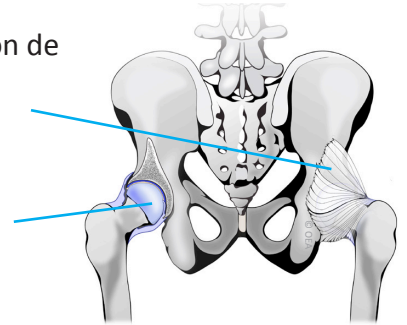
Bursitis de Cadera



Anatomía Normal

Articulación de la cadera

Cápsula articular

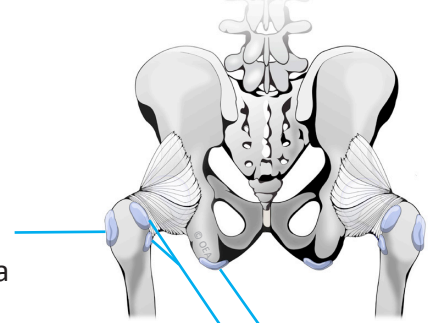


Bursas de una cadera normal

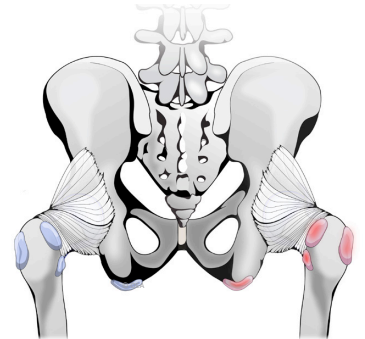
Bursa Trocantérea

Bursa Glútea

Bursa Isquiática



Bursa de la cadera inflamada



Tara M. Sheridan, M.D.
Pain Medicine/Anesthesiology



31469 Rancho Pueblo Road,
Suite 101
Temecula, CA 92592
Phone: 951-303-3718
Fax: 951-303-0451