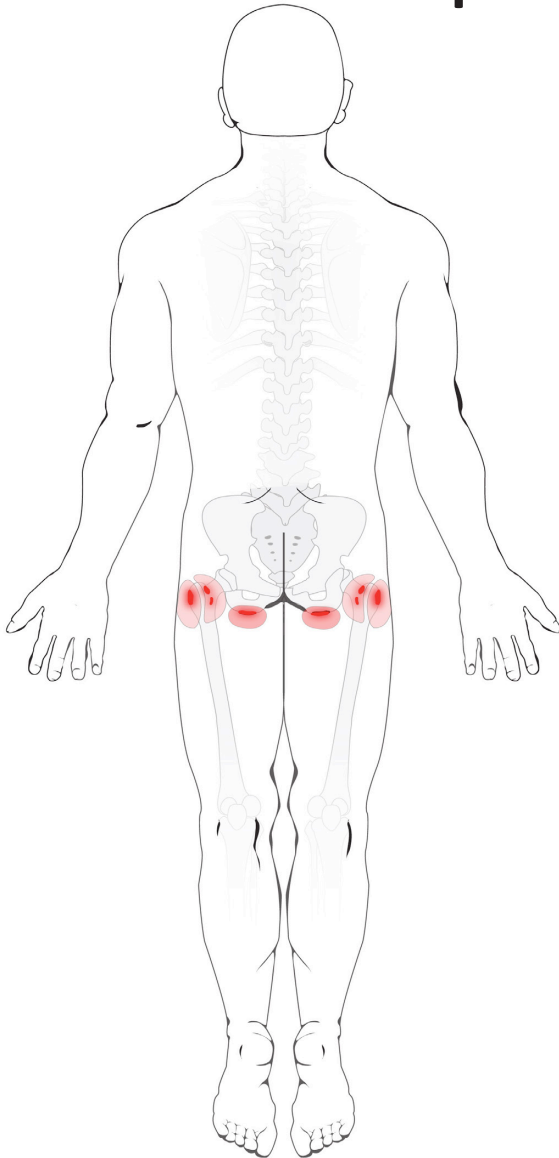


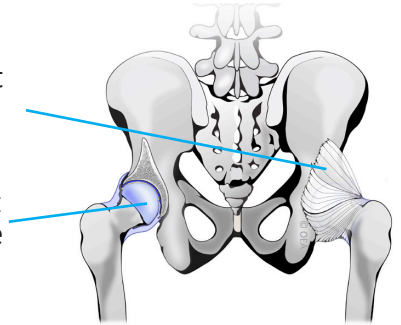
# Hip Bursitis



## Normal Anatomy

Hip Joint Capsule

Hip Joint Cartilage

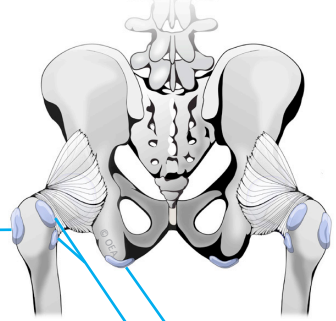


## Normal Hip Bursae

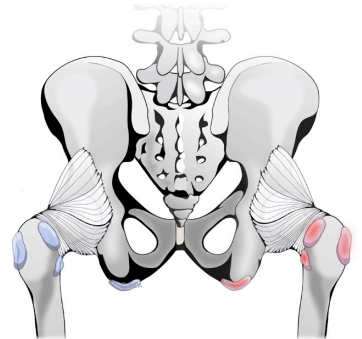
Trochanteric Bursa

Gluteal Bursae

Ischial Bursa



## Inflamed Hip Bursae



Tara M. Sheridan, M.D.  
Pain Medicine/Anesthesiology



31469 Rancho Pueblo Road,  
Suite 101  
Temecula, CA 92592  
Phone: 951-303-3718  
Fax: 951-303-0451